Exposure of FAI – A squeezed labrum as the reason for limitation of movement and pain

Robert Cichon(1), Dominik Raab(1), Andrea Lazik Palm(2), Jens M. Theysohn(2), Stefan Landgraeber(3) , Wojciech Kowalczyk(1)

(1) Chair of Mechanics and Robotics
University of Duisburg-Essen,
D-47057 Duisburg, Germany

(2) Inst. for Diagnostics and Interventional Radiology and Neuroradiology,
University Hospital Essen,
D-45147 Essen, Germany

(3) Clinic for Orthopedics,
University Clinic Essen,
D-45147 Essen, Germany
E-Mail: robert.cichon@uni-due.de
Web: www.uni-due.de/lmr

Abstract – In recent years, Femoroacetabular Impingement (FAI) has become an increasingly common orthopedic disease. In literature this disease is described as an abnormal contact between femur and acetabular rim caused by bony deformities, which leads to limitation of movement and pain and, in long-term, damage of the cartilage. [1] This deformity occur either at the femoral neck (cam-type) or at the acetabular rim (pincer-type) or combined. A possible treatment is the arthroscopic removal of the overlapping bone, which is exclusively a subjective assessment of the attending physician based on static imaging, e.g. MRI, and movement tests, which is therefore only a semi-quantitative diagnosis. A more exact surgery planning is possible using dynamic multi-body simulations.

The detection of the FAI is performed by investigating the range of motion using a Motion Capture system. During the measurement the pain is recorded with a pressure detecting bellow. After this investigation, a MRI scan is performed using a comprehensive thin layer protocol with a slice thickness of 1.5mm. MRI data of Acetabulum, Femur and Labrum are manually segmented and CAD models as well as FEM models are generated illustrated in Figure 1. The contact modeling between Labrum and Femur was generated using the Pure Penalty algorithm, Labrum and Acetabulum remain bonded. The material properties for the bony parts is lin. cortical bone (E=1,2 GPa, ϑ=0,4 [2]) and for the Labrum (E=20 MPa , ϑ=0,4 [3]). The movement in the simulation is controlled using the determined maximum angles of the motion analysis.

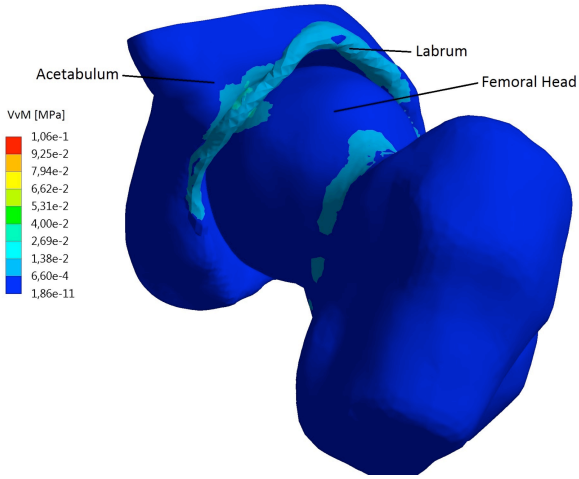

Fig.1: Patient-Specific Hip Model Including Labrum, Femur and Acetabulum.

The visualization and quantification of the joint movement show a contact of labrum and femur. Comparing this simulation result with the motion analysis results, the patient applied the pain sensor in the same angle range of 11.5° internal rotation and 33° flexion. Deformations and stresses can be determined and are available at the contact area visible in Figure 1.

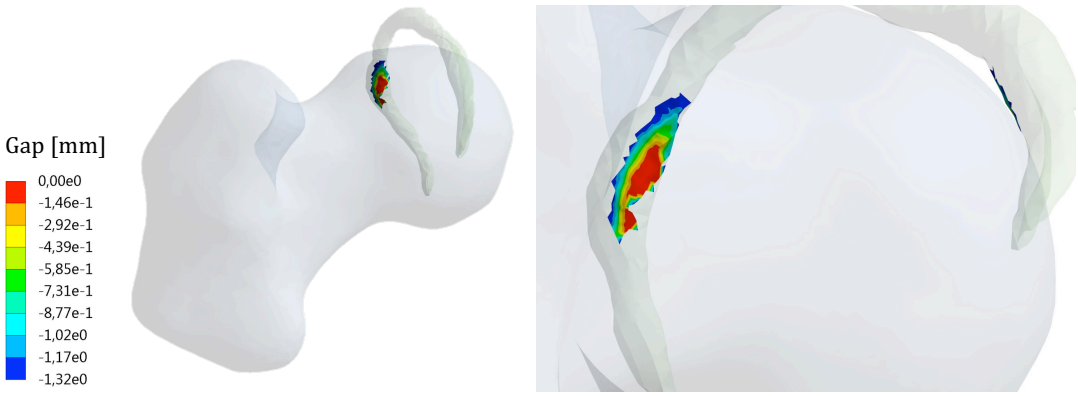

Fig.2: Contact Modeling of a Patient-Specific Hip Model: Gap Analysis Show Contact Between Femur and Labrum.

In Figure 2 the Gap Modeling of ANSYS is showed: There is a contact area between Femur and Labrum.
An automatic MRI segmentation is necessary to standardize this diagnose possibility. The surgical treatment can be better planned to remove the bony deformity to ensure no squeezing of the labrum. Further evaluations are possible using computer-assisted techniques, such as FEM. Additionally, the navigation-assisted surgery can optimize the surgical outcome. In future studies, articulating cartilages and muscles forces, as well as cancellous bone should be implemented to ensure a more realistic simulation of the Biomechanics of the human hip joint. For validation a patient study is needed.

References

[1] O.Marin Pena, Femoroacetabular Impingement, Springer-Verlag, 2012.

[2] Tran et al., Experimental and computational studies on the femoral fracture risk for advanced core decompression, Clin Biomech, Vol. 29, 412-417

[3] Ferguson et al., The material properties of the bovine acetabular labrum, J Rthop Res, Vol. 19, 5: 887-896